

# ABBERANT REMODELING OF THE NEURAL RETINA IN THE GHL TRANSGENIC MOUSE


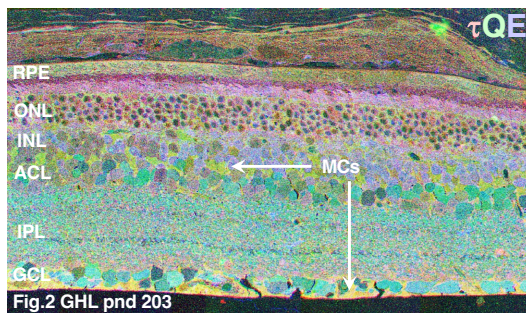
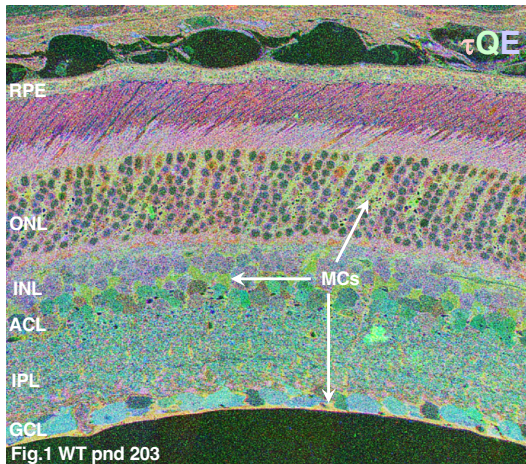


BW JONES, RE MARC, JM FREDERICK, W BAEHR, CB WATT, J-H YANG, MV SHAW · MORAN EYE CENTER  
UNIVERSITY OF UTAH · Abstract VR0085 · Support: RM [NIH EY02576, Jules and Doris Stein RPB Professorship];  
WB [NIH EY08123, RPB Senior Investigator, FFB Center Grant, Grant from the Macula Vision Research  
Foundation]; Research to Prevent Blindness

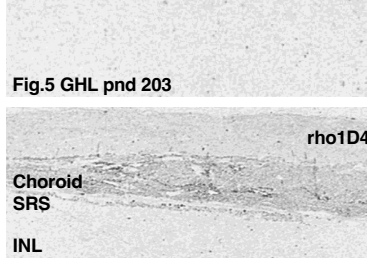
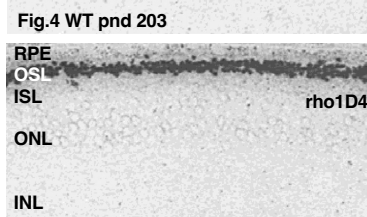
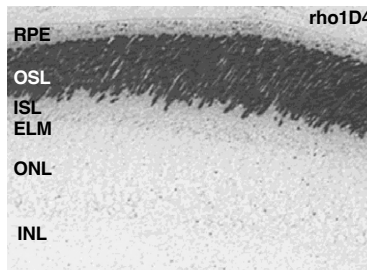


**Purpose:** We sought to test the hypothesis that the neural retina is largely preserved in photoreceptor-based retinal degenerations, and, by extension, in human retinitis pigmentosa (RP).

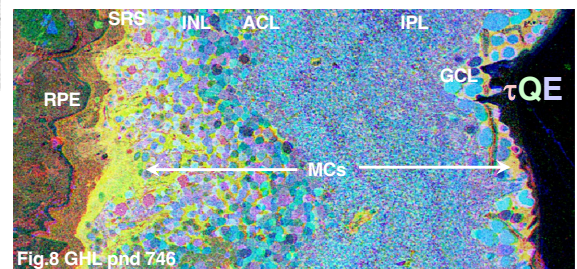
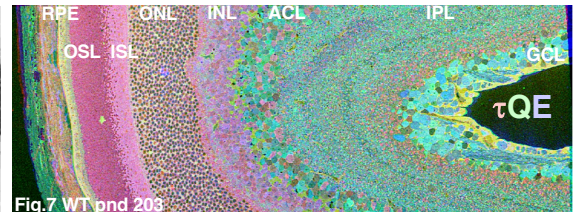
**Methods:** Rod photoreceptors slowly degenerate in the GHL transgenic triple mutant rhodopsin mouse line (V20G, P23H, P27L). Retinas in various stages of degeneration were assembled into serial 250 nm sample arrays, probed for rhodopsin, L-ala, L-asp, L-glu, L-gln, glutathione, taurine and GABA signals, and analyzed by computational molecular phenotype (CMP) visualization.



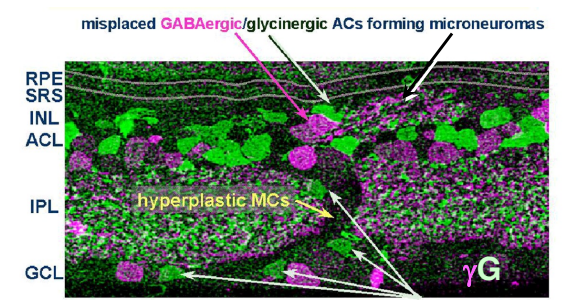
**Figs 1-3.** CMP display of tau (red), gln (green), glu (blue) signals in a single tissue array containing retinas from three animals: WT postnatal day (pnd) 203 (Fig. 1); transgenic GHL (on a WT background) pnd 203 (Fig. 2); transgenic GHL pnd 746 (Fig. 3). As the animals age, photoreceptors degenerate first, but eventually there is massive neuronal loss with remodeling of the surviving neural retina. The remodeling includes enlargement of amacrine cell somas, proliferation of glycinergic amacrine cell dendrites, Müller cell hyperplasia and "eruptions", inner plexiform layer deformation, abundant microneuroma formation and movement of some remaining bipolar, amacrine and ganglion cells into inappropriate layers. ACL, amacrine cell layer; GCL, ganglion cell layer; INL, inner nuclear layer; IPL, inner plexiform layer; MCs, Müller cells; ONL, outer nuclear layer; RPE, retinal pigment epithelium; SRS, subretinal space.



**Figs 4-6.** Sections (250 nm) from the tissue array in fig. 1-3 labeled with rho1D4 targeting WT rhodopsin (courtesy of Dr. Robert Molday). The WT retina (Fig. 4) displays strong rod outer segment rhodopsin signal. Outer segments are smaller in the rods of the GHL pnd 203 animal (Fig. 5) but the signal strength is unchanged. No WT rhodopsin is synthesized in the GHL pnd 746 animal (Fig. 6). OSL, outer segment layer; ISL, inner segment layer.



**Figs. 7-8.** CMP display of tau (red), gln (green), glu (blue) signals in horizontal sections through WT pnd 203 (Fig 7) and GHL pnd 746 (Fig 8) retinas. These analyses reveal Müller cell hyperplasia (yellow), altered neuronal metabolism (enhanced blue) and extensive loss of bipolar cells in the aged GHL transgenic retina.



**Fig. 9.** Mixed microneuromas of GABA (magenta) and glycine (green) immunoreactive process form in the remnant subretinal space. Bipolar cells are virtually absent in many areas, with glycinergic amacrine cells migrating along the Müller cell eruptions into the ganglion cell layer. Glycinergic terminals in the inner plexiform layer are also hyperplastic.

**Results:** Remodeling of GHL retinas progresses in severity with age. Early stages of rod remodeling and mild photoreceptor loss are accompanied by obvious inner nuclear layer alterations and aberrant, elevated photoreceptor aspartate signals (data not shown). After complete loss of rods, implied by loss of WT rhodopsin synthesis, severe abnormalities appear in the neural retina, including microneuromas of neuropil erupting from the inner plexiform layer or arising *de novo* and ramifying in the remnant subretinal space. Estimates oblique sections indicate no less than 30,000 microneuromas are formed across the retina. Some ganglion cell somas were displaced along radially disordered columns of neuropil and their altered shapes suggested compression, traction and active movement. The oldest retinas displayed profound focal loss of bipolar cells with hypertrophy of survivor amacrine cells and Müller cells, the latter often encapsulating blood vessels. Active movement of all remaining cell types throughout the retinal space was seen. CMP analysis revealed altered neuronal signatures were altered, implying altered turnover rates and oxidative metabolism in survivor cells of the GHL transgenic neural retina.

**Conclusions:** Data from the GHL transgenic triple mutant mouse model (V20G, P23H, P27L) parallels those from human RP retina in displaying marked metabolic aberrations, massive neuronal cell loss and, perhaps more seriously, active pathologic (and likely dysfunctional) ectopic and, possibly, intrinsic patches of neuropil. The concept that the neural retina is largely preserved and experiences only minor changes in the outer retina is incorrect. Pathology in retinal circuitry is most certainly present and may begin soon after the onset of rod death.